



PATIENT

River Song Messick

SPECIES

Canine

BREED

Beagle Dachshund Mix

SEX

Female Spayed

AGE

11.5 years

WEIGHT

26lbs

INTERPRETED BY

Maggie Machen Lamy,
DVM, DACVIM
(Cardiology)

IMAGING PERFORMED BY

Carey Zumpano, DVM

HOSPITAL NAME

Pikesville Animal
Hospital

REFERRING VET

Dr. Zumpano

INVOICE

45799

DATE

11/18/25

PRESENTING CLINICAL SIGNS

History: Presented for increased coughing in the last week. Grade 2-3/6 murmur present on exam. Cardiomegaly on CXR. Started on Vetmedin and echo performed 1 day later. BP: 130mmHg.

RADIOGRAPHIC FINDINGS *NOTE: Images submitted for supplemental cardiac information only.

Cardiomegaly. No obvious evidence of CHF.

ECHOCARDIOGRAM FINDINGS

2D, m-mode, color flow and doppler imaging is available. Diffuse thickening of mitral valve leaflets with prolapse into the left atrial lumen. Severe eccentric mitral regurgitation with severe left atrial dilation. LV dilation with hyperdynamic myocardial function. The tricuspid valve appears mildly thickened with mild tricuspid regurgitation. TR velocity is normal. Right heart is normal. The pulmonic and aortic valves are normal in morphology and mobility. Normal pulmonic and aortic outflow velocities. No aortic or pulmonic insufficiency. No pericardial or pleural effusion noted. No obvious cardiac tumors observed.

CARDIAC CHART

CANINE CARDIAC PARAMETERS	MR VMAX (m/s)	TR VMAX (m/s)	LA/AO (Boon method)	LA/AO (Heart Base; Swe)	FS (%)	EF (%)	EPSS (cm)
NORMAL PARAMETER	4.5-5.5	<2.7	1.3	<1.6	28-40	40-100	<0.6
PATIENT	5.2	2.8	NM	2.2	50	88	NM
CANINE CARDIAC PARAMETERS	HR (BPM)	AV VMAX (m/s)	PV MAX (m/s)	BODY WEIGHT	LA 2D short axis Base view (cm)	LVIDd Avg; 2D and m-mode short axis (cm)	LVIDs Avg; 2D and m-mode short axis (cm)
NORMAL PARAMETER	50-100	0.7-1.7	0.7-1.6	BELOW	BELOW	BELOW	BELOW
PATIENT	NM	1.5	0.7	11.8	3.5	4.7	2.3
*Normal chamber parameters expressed as a mean value (SD)				3	1.27 (5.3)	2.46 (2.46)	1.36 (5.5)
BODY WEIGHT DEPENDENT PARAMETERS				5	1.40 (4.5)	2.74 (5.2)	1.60 (4.7)
*Note: All measurements based upon multi-modal images and methods. An average value is reported.				10	1.50 (3.8)	3.27 (3.5)	2.06 (3.1)
				15	1.83 (2.0)	3.71 (2.4)	2.43 (2.1)
				20	2.02 (1.9)	4.14 (2.2)	2.80 (2.0)
Adapted from June Boon, Veterinary Echocardiography, 1998				25	2.18 (2.4)	4.48 (2.9)	3.10 (2.5)
Rishniw M and Hollis NE, J Vet Intern Med 2000; 14:429-435				30	2.33 (3.3)	4.83 (3.9)	3.39 (3.4)
Hansson et al, Vet Rad and Ultrasound 2002				35	2.48 (4.3)	5.17 (5.0)	3.69 (4.5)
Bonagura et al. Echocardiography: principles of interpretation, Vet Clin North Am 15:1177, 1995				40	2.62 (5.2)	5.48 (6.1)	3.96 (5.4)
				50	2.88 (7.1)	6.07 (8.3)	4.46 (7.4)

INTERPRETATION OF THE FINDINGS & FURTHER RECOMMENDATIONS

The murmur is due to chronic degenerative valve disease causing severe mitral and mild tricuspid regurgitation. Significant left atrial and ventricular enlargement indicate the risk for spontaneous congestive heart failure is elevated. No obvious additional issues are noted.

A cough in this patient with severe heart disease is likely multi-factorial in origin, including mainstem bronchi compression and/or potentially some degree of upper or lower airway disease. Early CHF/pulmonary edema should also be considered; however, this is less likely based upon the CXR results as well as a reported cough in the absence of labored breathing. Recommend



PATIENT

River Song Messick

SPECIES

Canine

BREED

Beagle Dachshund Mix

SEX

Female Spayed

AGE

11.5 years

WEIGHT

26lbs

INTERPRETED BY

Maggie Machen Lamy,
DVM, DACVIM
(Cardiology)

IMAGING PERFORMED BY

Carey Zumpano, DVM

HOSPITAL NAME

Pikesville Animal
Hospital

REFERRING VET

Dr. Zumpano

INVOICE

45799

DATE

11/18/25

institute cardiac supportive medications including a weak diuretic (spironolactone) for potential survival benefit and advise close monitoring at home for need for Lasix therapy. Cough suppression (up to q4-6 hours) may also be helpful for any component of a mechanical cough. **Monitoring of sleeping breathing rates is recommended as the best way to screen for CHF at home.**

Omega fatty acid supplementation and mild salt restriction may also be of some long-term benefit. Monitor for development of a worsening cough, labored breathing, exercise intolerance or collapse episodes. Long term prognosis is guarded to poor with stage (late) B2 disease, with risk for CHF in the near future. Once diagnosed, the average survival time for canine patients is 8-9 months on medications; however, most are able to maintain a good quality of life for that period. Patient will always be at risk for progression to CHF, development of arrhythmias/LA tear, syncope and/or sudden death in the future.

Elective anesthesia is not advised, as there is high risk for complication. Risk: benefit ratio should be considered. Consider consultation with and/or referral to a facility with an anesthesiologist. Should you elect to proceed, cardiac protective drug choices (opioid/benzodiazepine premedication, propofol or alfaxalone induction, iso or sevoflurane gas) are recommended. Pre-oxygenate for 5-10 minutes prior to induction and recover in O2 cage. Monitor for arrhythmias, hypotension, and hypoxia both intra and post-operatively and intervene as necessary. Moderate IV fluid restriction is recommended to avoid fluid overload, while considering comorbidities, hydration status, BP, etc. Avoid heart rate stimulating drugs such as atropine unless clinically indicated.

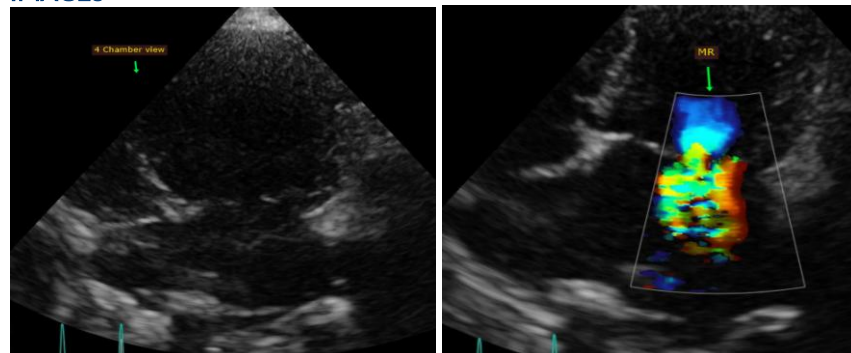
PLAN

Baseline BP recommended. Continue Pimobendan 0.3mg/kg PO q12h. Institute Spironolactone 1-2mg/kg PO q12h. If BP > 130mmHg, institute ACE-I (benazepril or enalapril) 0.5mg/kg PO q12h. Consider hydrocodone with homatropine for QOL (0.2-0.4mg/kg PO up to q4-6 hours PRN for cough; available in 5/1.5mg tabs and 5mg/5ml liquid suspension).

A renal panel and BP are recommended in 1-2 weeks, then every 3-4 months lifelong to ensure tolerance of medications.

A recheck echocardiogram is recommended in 6 months to screen for progression, sooner if clinical signs arise in the interim.

IMAGES





PATIENT

River Song Messick

SPECIES

Canine

BREED

Beagle Dachshund Mix

SEX

Female Spayed

AGE

11.5 years

WEIGHT

26lbs

INTERPRETED BY

Maggie Machen Lamy,
DVM, DACVIM
(Cardiology)

IMAGING PERFORMED BY

Carey Zumpano, DVM

HOSPITAL NAME

Pikesville Animal
Hospital

REFERRING VET

Dr. Zumpano

INVOICE

45799

DATE

11/18/25

The information and recommendations provided are based on the images presented by the referring veterinarian. No evaluation can be communicated regarding pathology that was not visible in the image/video clips provided.

Thank you for this referral. This report was generated using transcription software, and minor dictation errors may be present. If the clinical or image interpretation does not parallel your findings or if I can be of any further assistance, please contact me.

Maggie Machen Lamy, DVM
Diplomate of the American College of Veterinary Internal Medicine (Cardiology)
info@sonopath.com